

# A CASE REPORT OF NEUROTROPHIC KERATITIS

## ABSTRACT

**Introduction :**Neurotrophic keratitis (NK) is a rare corneal disease caused by damage to trigeminal nerve supply, leading to poor corneal healing and epithelial breakdown. Its key feature is reduced or absent corneal sensation, which can progress to ulcers, corneal melting, or perforation.

**Material and Methodology :**This case report describes a 55-year-old male presented to Maharani Laxmi Bai Medical College with Neurotrophic keratitis in the left eye. A detailed ocular and systemic examination was performed. The patient was admitted for conservative management with conventional treatment modalities and post treatment, the patient's condition showed improvement.

**Management and Treatment :** There is no definitive pharmacological treatment available for neurotrophic keratitis (NK), and management mainly focuses on supportive care and prevention of complications. Growth factors and metalloprotease inhibitors are two new and promising treatments for NK, according to certain experimental and clinical data.

**Conclusion :**NK is challenging for ophthalmologists to diagnose and treat, with current therapies mainly focused on preventing corneal perforation, promoting healing, and halting disease progression. However, no available treatment reliably restores corneal sensitivity or improves visual acuity. Emerging therapies, including growth factors, and ongoing clinical trials offer hope for more effective future treatments.

## INTRODUCTION

Neurotrophic keratitis (NK) is a rare degenerative corneal disease caused by impairment of trigeminal innervation leading to corneal epithelial breakdown, impairment of healing, and development of corneal ulceration, melting, and perforation. The hallmark of NK is a decrease or absence of corneal sensation.<sup>[1]</sup>

Magendie first identified NK as "neuroparalytic keratitis" and conducted experiments to support his theory that trophic nerve fibers in the trigeminal nerve regulate the tissue metabolism.<sup>[2]</sup> It is now known that the trigeminal nerve plays a crucial role in preserving the anatomical integrity and functionality of the ocular surface by supplying the cornea with trophic nutrients and corneal sensibility.<sup>[3]</sup> Through the secretion of cytokines, neuropeptides, and neuromediators, the ocular surface epithelium, tear gland, and sensory and autonomic nerve fibres regulate each other's structures and functions.<sup>[1, 3]</sup>

Impairment of corneal trigeminal innervation causes morphological and metabolic epithelial disturbances and leads to development of recurrent or persistent epithelial defects. Recurrent or permanent epithelial deficiencies emerge as a result of morphological and metabolic epithelial changes brought on by impairment of corneal trigeminal innervation

40 **GRADING**

41 **Stage I (Mild):** Characterized by decreased tear break-up time and irregular surface cells (punctate  
42 keratopathy), often closely mimicking standard dry eye disease.

43 **Stage II (Moderate):** Defined by the development of persistent, recurrent open wounds (epithelial  
44 defects) on the cornea. These wounds often have smooth edges because the cornea's natural  
45 healing ability is hindered.

46 **Stage III (Severe):** The most advanced phase, involving corneal melting, deep ulcers, and a high risk  
47 of corneal perforation.

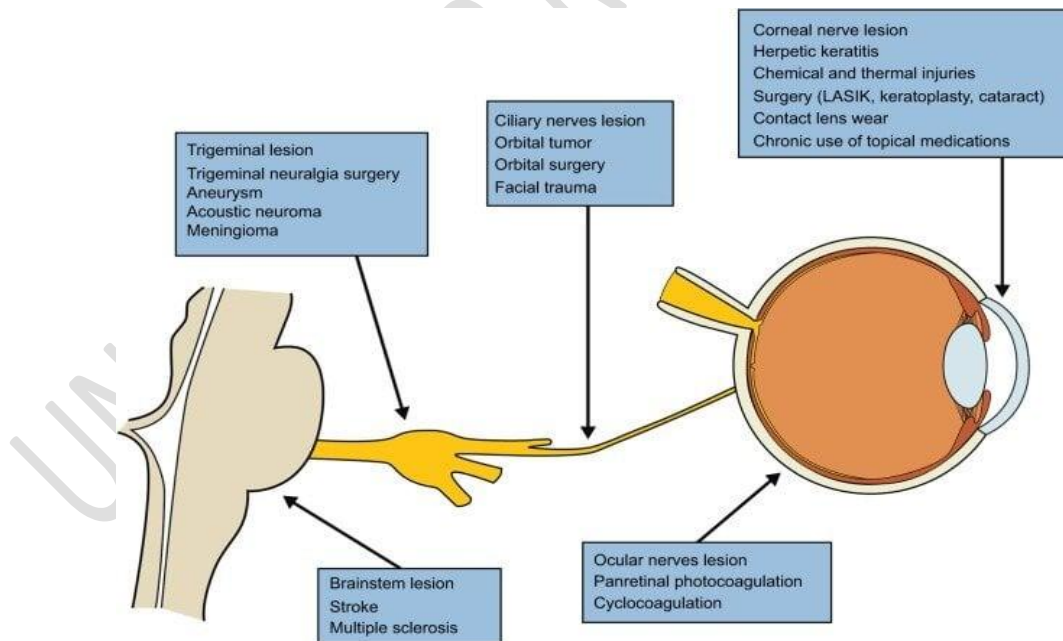
48

49 **CAUSES**

50 NK may arise as a result of ocular and systemic disorders linked to injury at any level of the fifth  
51 cranial nerve (trigeminal nerve), from the corneal nerve endings to the trigeminal nucleus. Herpetic  
52 keratitis, cerebral space-occupying lesions, and/or neurosurgical procedures that harm the  
53 trigeminal ophthalmic branch are the most frequent causes of impaired corneal sensation. Chemical  
54 burns, physical trauma, corneal dystrophy, long-term topical drug use, and anterior segment surgery  
55 involving nerve transection are additional ocular reasons of corneal sensitivity degradation. Corneal  
56 anaesthesia is also linked to a number of systemic illnesses, such as leprosy, multiple sclerosis,  
57 diabetes, and congenital abnormalities.<sup>[1]</sup>

58

59



60

61 **Figure 1 : Causes of Neurotrophic Keratitis**

62 **MATERIAL AND METHODOLOGY**

63 This is a case report of a 55 years old male patient who came to Maharani LaxmiBai Medical College,  
64 Jhansi, with Neurotrophic Keratitis in left eye and immature senile cataract in right eye. Detailed

65 ocular and systemic examination were done to rule out any other abnormalities, which included  
66 history of the presenting illness, visual acuity using Snellen's chart, corneal sensitivity, complete  
67 ocular examination using slit lamp, intra-ocular pressure using non-contact tonometer. Blood was  
68 sent for routine laboratory investigations. Patient is admitted for conservative management using  
69 conventional treatment options and the condition of patient is improved.

70

71

## 72 **CASE REPORT**

73 A 55 years old male presented with complaints of Diminution of vision in left eye from past 3 months  
74 which was insidious in onset and gradually progressive in nature. It was associated with watering,  
75 redness and photophobia. He has a past history of chronic use of multiple topical medications. No  
76 past history of pain, headache or trauma. No prior history of wearing spectacles. There is no known  
77 instance of ischemic heart disease, diabetes, asthma, chronic obstructive pulmonary disease [COPD],  
78 or hypertension.

79

80

## 81 **OCULAR EXAMINATION**

82

O/E	RIGHT EYE	LEFT EYE
Vision (using snellen's chart)	6/24	Hand movement +ve
Best Corrected Visual Acuity	6/12 (-1.25DS/-0.50DC @ 90°)	Hand movement +ve
Perception of light	Present	Present
Projection of rays	Present in all 4 quadrants	Present in all 4 quadrants
Orbital Margins	Intact on palpation	Intact on palpation
Extraocular Movements	WNL in all directions of gaze	WNL in all directions of gaze
Eyelid/Eyebrow	WNL	WNL
Intraocular pressure (non-contact tonometry)	14 mmhg	11 mmhg

83

84

Table 1 : Ocular findings of patient

85

86

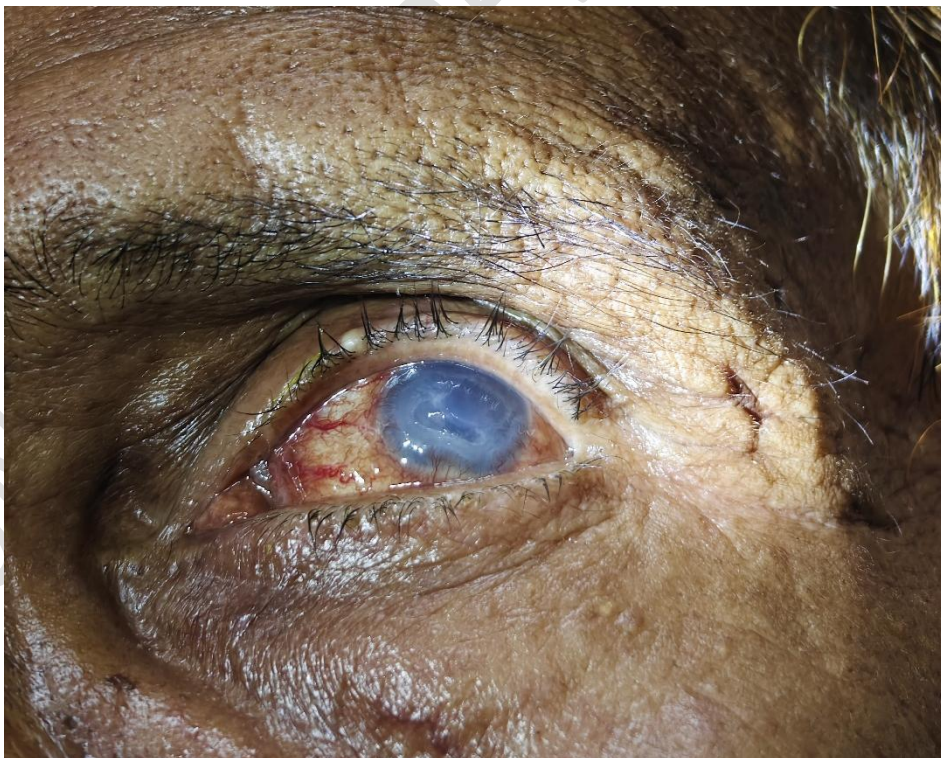
## 87 **SLIT LAMP EXAMINATION**

88

O/E	RIGHT EYE	LEFT EYE
Cornea	WNL	<ul style="list-style-type: none"> <li>• Stromal ulceration/melting characterised by crater-like defect</li> <li>• Stromal edema</li> <li>• Sterile stromal necrosis</li> <li>• Stain positive persistent epithelial defect</li> <li>• Neovascularization</li> <li>• Reduced corneal sensations</li> </ul>
Conjunctiva	WNL	Diffuse congestion
Anterior Chamber	Normal depth (VH4)	Shallow (VH2)
Iris	Normal colour/normal pattern	Normal colour/normal pattern
Pupil	Round/Regular/Reactive	Round/Regular/Reactive
Lens	Greyish white reflex	Glassy Reflex
Fundal glow	Fair	Poor

89  
90  
91

**Table 2 : Slit Lamp Findings of patient**



92  
93  
94

**Figure 2 : Patient's eye on the day of presentation (day 0)**

**PROVISIONAL DIAGNOSIS**

95 On the basis of history and ocular examinations, the provisional diagnosis is **Left eye Neurotrophic**  
96 **Keratitis (stage III)**

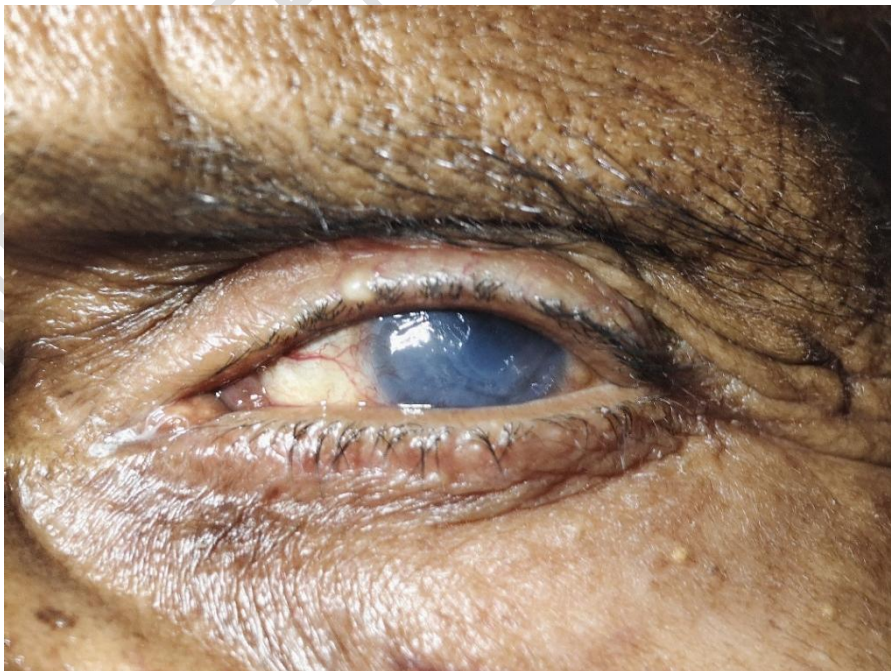
97 **MANAGEMENT AND TREATMENT OPTIONS**

98 There are no pharmacological therapies for NK. However, at every level of the severity of the  
99 disease, the corneal surface may be improved by using artificial tears without preservatives.  
100 Although topical steroids have been suggested for NK to manage ocular inflammation (if it exists),  
101 their usage should be carefully examined as they may raise the risk of corneal melting and  
102 perforation by preventing stromal repair.<sup>[1, 4, 5]</sup> Topical nonsteroidal anti-inflammatory medications  
103 should be avoided as they may also impede the healing process.<sup>[6]</sup> Short-acting cycloplegic and  
104 mydriatic agent can also be used as an adjunctive, supportive therapy rather than a primary  
105 treatment. It relieves pain caused by ciliary muscle spasm and helps prevent iris adhesions  
106 (synechiae) when secondary inflammation occurs. Antivirals are essential as prophylaxis or  
107 suppressive therapy against viral reactivations, but they do not directly treat neurotrophic keratitis.  
108 Antivirals stop quiet, recurrent viral infections from seriously harming an already weakened cornea  
109 when neurotrophic keratitis is brought on by herpes simplex or herpes zoster. In order to prevent  
110 infection in eyes with NK at stages 2 and 3, topical antibiotic eye drops are advised.

111 **R**

112 Patient was started with following medications :-

- 113 • **E/d Carboxymethyl Cellulose 1% 1d 1 hrly**
- 114 • **E/d Moxifloxacin 0.5% 1d QID**
- 115 • **E/d Prednisolone 1% 1d QID**
- 116 • **E/d Homatropine 2% 1d TDS**
- 117 • **Tab Acyclovir 400mg x 5times/day**



118

119

**Figure 3 : Patient's eye on 3<sup>rd</sup> day post treatment**

120

**FOLLOW UP**

121 Patient was discharged with following medications and called for follow up after 1 week

- 122 • E/d Carboxymethyl Cellulose 1% 1d 6times/day
- 123 • E/d Moxifloxacin 0.5% 1d QID
- 124 • E/d Prednisolone 1% 1d 3/2/1 times/day/week
- 125 • E/d Homatropine 2% 1d TDS
- 126 • Tab Acyclovir 400mg x 5times/day

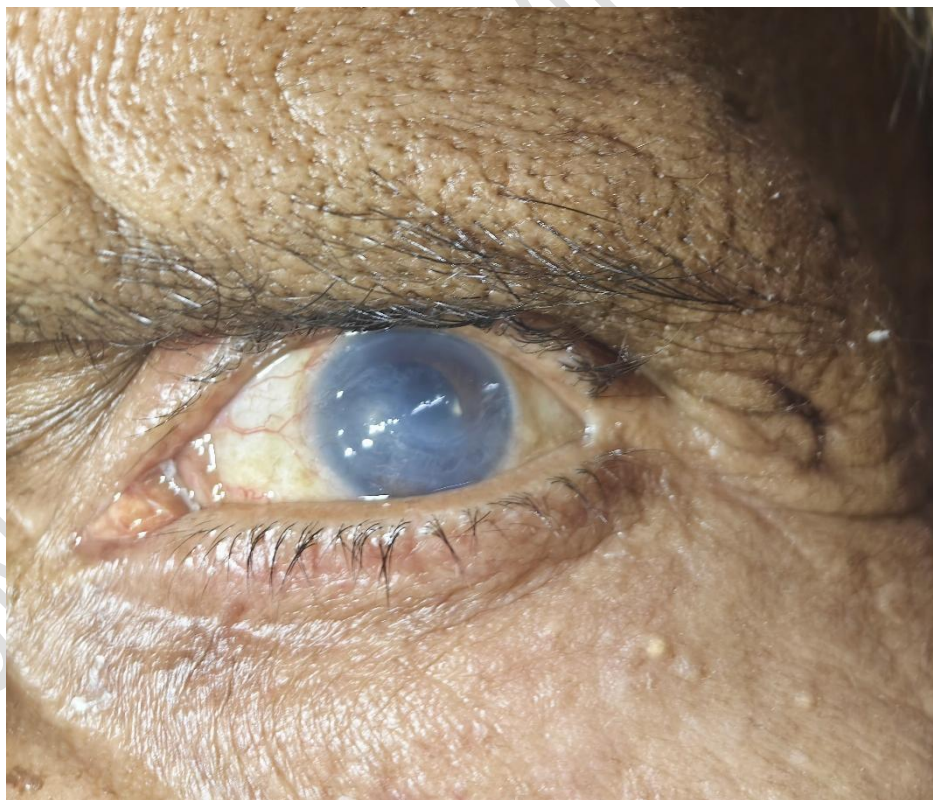127

128

129 **SLIT LAMP EXAMINATION**

- 130 • Corneal sensations got back to normal
- 131 • Fluorescein stain negative
- 132 • Stromal ulcerations resolved
- 133 • Mild stromal edema present
- 134 • Neovascularisation resolved
- 135 • Conjunctival congestion resolved

136



137

138 **Figure 3 : Patient's eye on 7<sup>th</sup> day post treatment follow up**

139

140

141 **FUTURE DEVELOPMENTS**

142 For NK, new medicinal and surgical interventions have been suggested and are presently being  
143 researched. <sup>[1, 4, 7]</sup> Six NK patients with unilateral facial palsy with corneal anesthesia have shown  
144 improved results following surgical operations of sensory neurotization by insertion of the  
145 contralateral supraorbital and supratrochlear nerves to the anesthetic corneal limbus. <sup>[8]</sup>

146 In one patient with NK brought on by herpes zoster keratitis, the use of a Boston keratoprosthesis  
147 (Boston K-Pro; Massachusetts Eye and Ear Infirmary, Boston, MA, USA) restored visual function at a  
148 4-month follow-up. <sup>[9]</sup> Numerous pharmacological therapies have been shown to be effective in  
149 promoting the healing of corneal ulcers in NK, according to open studies. Eight out of eleven patients  
150 (73%) who received treatment with eye drops containing RGTA<sup>®</sup> (Cacicol20<sup>®</sup>; OTR3, Paris, France), a  
151 matrix agent that mimics heparansulfate, experienced full healing, with the NK ulcer closing after an  
152 average of 8.7 weeks. <sup>[10]</sup>

153 In a another trial, eye drops containing thymosin beta-4—a synthetic version of the naturally  
154 occurring 43-amino acid G-actin sequestering molecule—were administered to nine NK patients with  
155 PED. Three of these patients had recovered by the conclusion of the 30-day follow-up period, and  
156 one patient had fully recovered by the end of the therapy period. <sup>[11]</sup> In an average of 22 days,  
157 autologous serum (50%) eye drops caused corneal healing in 23 out of 25 NK eyes. <sup>[12]</sup> Additionally, a  
158 retrospective study comparing the effectiveness of AMT with autologous serum eye drops found  
159 that multilayer AMT was superior for healing deep corneal ulcers following herpes simplex keratitis.  
160 <sup>[13]</sup>

161 All eyes treated with topical non-gelified platelet-rich plasma for PED caused by various disorders,  
162 including NK, healed completely in 6–32 days. <sup>[14]</sup> Furthermore, after receiving umbilical cord serum  
163 eye drops for an average of four weeks, 28 NK patients had total corneal healing. <sup>[15]</sup> Neuropeptides  
164 and growth factors have been suggested for the therapy of NK in a number of studies. Larger  
165 investigations, however, could not corroborate early findings about the effective use of epidermal  
166 growth factor eye drops in NK patients. <sup>[16]</sup>

167 In an open research, 25 patients with NK received topical treatment with substance P and insulin-like  
168 growth factor-1; at 4 weeks, 73% of patients showed complete repair of epithelial abnormalities. <sup>[17]</sup>  
169 Eleven NK patients were treated with PED using a combination of substance P-derived peptide,  
170 phenylalanine–glycine–leucine–methionine–amide, and insulin-like growth factor-1, which resulted  
171 in total epithelial resurfacing in 89% of instances. <sup>[18]</sup> One extremely potential future therapeutic  
172 strategy for the prevention and treatment of NK is the use of nerve growth factor eye drops.  
173 Recovery from NK may result from nerve growth factor's ability to enhance tear and nerve function  
174 as well as promote corneal epithelial and sensory nerve survival and regeneration. Patients with  
175 moderate to severe NK (stages 2 and 3) responded well to topical nerve growth factor treatment.  
176 After using nerve growth factor eye drops for 12 days to 6 weeks, 100% of 55 patients in two open,  
177 uncontrolled investigations showed complete corneal healing.

178

179

180

181

182

183 **CONCLUSION**

184 For ophthalmologists, diagnosing and treating NK can be difficult. The goals of the current  
185 medication and surgical interventions are to prevent corneal perforation, encourage healing, and  
186 stop the condition from getting worse. Nevertheless, there are currently no treatments that can  
187 enhance corneal sensitivity degradation and restore visual acuity. Numerous cutting-edge therapies,  
188 including growth factors, may enhance the therapeutic outcome of NK, according to experimental  
189 and clinical data. New treatments for this orphan disease will be made possible by the results of  
190 current clinical trials.

191

192

### 193 **DISCLOSURE**

194 All the photographs used in this journal have been published after obtaining informed consent and  
195 permissions from the patient.

196 Financial support and sponsorship: Nil

197 Conflicts of interest: Nil

198

199

### 200 **REFERENCES**

201 1. Bonini S, Rama P, Olzi D, Lambiase A. Neurotrophic keratitis. *Eye (Lond)*. 2003;17:989–995.

202 2. Magendie F. De l'influence de la cinquieme paire de nerf sur la nutrition et les fonctions de l'oeil.  
203 [The influence of the fifth pair of nerves on nutrition and function of the eye]. *J PhysiolExpPathol*.  
204 1824;4:176–182. French.

205 3. Müller LJ, Marfurt CF, Kruse F, Tervo TM. Corneal nerves: structure, contents and function. *Exp*  
206 *Eye Res*. 2003;76:521–542.

207 4. Lambiase A, Rama P, Aloe L, Bonini S. Management of neurotrophickeratopathy.  
208 *Curr Opin Ophthalmol*. 1999;10:270–276.

209 5. Petroutsos G, Guimaraes R, Giraud JP, Pouliquen Y. Corticosteroids and corneal epithelial wound  
210 healing. *Br J Ophthalmol*. 1982;66: 705–708.

211 6. Hersh PS, Rice BA, Baer JC, et al. Topical nonsteroidal agents and corneal wound healing. *Arch*  
212 *Ophthalmol*. 1990;108:577–583.

213 7. Semeraro F, Forbice E, Romano V, et al. Neurotrophic keratitis. *Ophthalmologica*. October 2, 2013.  
214 [Epub ahead of print.]

215 8. Terzis JK, Dryer MM, Bodner BI. Corneal neurotization: a novel solution to  
216 neurotrophickeratopathy. *Plast Reconstr Surg*. 2009;123:112–120.

217 9. Pavan-Langston D, Dohlman CH. Boston keratoprosthesis treatment of herpes zoster  
218 neurotrophickeratopathy. *Ophthalmology*. 2008;115(Suppl 2):S21–S23

- 219 10. Aifa A, Gueudry J, Portmann A, Delcampe A, Muraine M. Topical treatment with a new matrix  
220 therapy agent (RGTA) for the treatment of corneal neurotrophic ulcers. *Invest Ophthalmol Vis Sci*.  
221 2012;53: 8181–8185.
- 222 11. Dunn SP, Heidemann DG, Chow CY, et al. Treatment of chronic nonhealing neurotrophic corneal  
223 epithelial defects with thymosin beta4. *Ann N Y Acad Sci*. 2010;1194:199–206.
- 224 12. Jeng BH, Dupps WJ Jr. Autologous serum 50% eye drops in the treatment of persistent corneal  
225 epithelial defects. *Cornea*. 2009;28:1104–1108.
- 226 13. Turkoglu E, Celik E, Alagoz G. A comparison of the efficacy of autologous serum eye drops with  
227 amniotic membrane transplantation in neurotrophic keratitis. *Semin Ophthalmol*. June 12, 2013.  
228 [Epub ahead of print.]
- 229 14. Geremicca W, Fonte C, Vecchio S. Blood components for topical use in tissue regeneration:  
230 evaluation of corneal lesions treated with platelet lysate and considerations on repair mechanisms.  
231 *Blood Transfus*. 2010;8:107–112.
- 232 15. Yoon KC, You IC, Im SK, Jeong TS, Park YG, Choi J. Application of umbilical cord serum eyedrops  
233 for the treatment of neurotrophic keratitis. *Ophthalmology*. 2007;114:1637–1642
- 234 16. Daniele S, Gilbard JP, Schepens CL. Treatment of persistent epithelial defects in neurotrophic  
235 keratitis with epidermal growth factor: a pre-liminary open study. *Graefes Arch ClinExp Ophthalmol*.  
236 1992;30: 314–317.
- 237 17. Yamada N, Matsuda R, Morishige N, et al. Open clinical study of eye-drops containing  
238 tetrapeptides derived from substance P and insulin-like growth factor-1 for treatment of persistent  
239 corneal epithelial defects associated with neurotrophic keratopathy. *Br J Ophthalmol*. 2008;92:896–  
240 900.
- 241 18. Nishida T, Chikama T, Morishige N, Yanai R, Yamada N, Saito J. Persistent epithelial defects due  
242 to neurotrophic keratopathy treated with a substance P-derived peptide and insulin-like growth  
243 factor 1. *Jpn J Ophthalmol*. 2007;51:442–447.

244

245

246

247

248

249

250

251

252

253

254

255

256

257

258

259

260

261

262

263

264

UNDER PEER REVIEW IN IJAR