

1
2
3 **A BIBLIOMETRIC EVALUATION OF RADIONUCLIDE IMAGING APPLICATIONS IN**
4 **TEMPOROMANDIBULAR JOINT DISORDERS.**
5
6
7
8

9 ***Abstract:***

10 Radionuclide imaging methods are techniques used for the functional evaluation of tissues, and the aim of the
11 present study was to evaluate the structure of the literature on radionuclide imaging methods in temporomandibular
12 joint imaging through bibliometric analysis. The study data were obtained from the Web of Science Core Collection
13 database, and R, RStudio, Biblioshiny, and Bibliometrix were used for the bibliometric analyses. The results
14 demonstrated an increase in annual scientific production, and the term “condylar hyperplasia” was identified as
15 occupying a central position within the literature. It was determined that the literature in this field mainly focuses on
16 condylar hyperplasia and temporomandibular joint metabolic activity.
17
18

19 ***Key words:*** Bibliometric Analysis, Scintigraphy, Positron Emission Tomography, Radionuclide Imaging, Single Photon Emission
20 Computed Tomography, Temporomandibular Joint.
21
22
23
24

25
26 **Introduction:** Nuclear medicine imaging methods constitute a field that utilizes radioactive
27 substances to evaluate tissue functions and diagnose diseases by examining the distribution of
28 these substances. Although these imaging methods are widely used in fields such as oncology
29 and cardiology, they are also employed in dentistry. However, these imaging modalities have
30 several disadvantages. Compared to anatomical imaging methods, they exhibit lower spatial
31 resolution. These high-cost imaging techniques require trained personnel and specialized
32 equipment. In addition, radiation exposure associated with these methods raises concerns for
33 patients, patients’ relatives, and healthcare professionals(1-3). However, these methods have the
34 capability to detect biochemical changes in cells before morphological alterations occur, thereby
35 enabling early diagnosis and providing information regarding cellular physiology(4).

36 Among these imaging modalities, scintigraphy uses gamma cameras and radionuclides to
37 identify regions with high cellular metabolic activity. These regions, where radionuclides
38 accumulate, are visualized as hot spots. Single Photon Emission Computed Tomography
39 overcomes the major limitation of scintigraphy, namely two-dimensional image formation, by
40 performing a 360° gamma camera scan and generating three-dimensional images. Positron
41 Emission Tomography is one of the most advanced imaging methods in nuclear medicine and,
42 unlike other imaging techniques, utilizes positron-emitting radioisotopes instead of gamma-
43 emitting radioisotopes. This allows the detection of smaller changes with greater sensitivity. One
44 of the most common applications of these imaging modalities in dentistry is the imaging of the
45 temporomandibular joint(3, 5-12).

46 Although numerous studies have been conducted on temporomandibular joint imaging in
47 dentistry using nuclear imaging methods, there is limited information in the literature regarding
48 the conceptual structure and thematic evolution of this field(13, 14). For this reason, it becomes
49 difficult to identify the development and progression of the field. Bibliometric analysis is a
50 useful method for overcoming these limitations. Through bibliometric analysis, the performance
51 and conceptual structure of a research field can be evaluated using quantitative findings(15-17).

52 The aim of this study was to investigate the use of radionuclide imaging methods in the
53 temporomandibular joint through Annual Scientific Production, Most Cited Documents
54 Analysis, Keyword Co-occurrence Analysis, Thematic Map Analysis, and Thematic Evolution
55 Analysis, and to evaluate the current status and evolution of the literature in this field.

56 **Materials and Methods:**The present study was designed as a bibliometric analysis investigating
57 the use of radionuclide imaging methods for temporomandibular joint imaging in the field of
58 dentistry. Due to the nature of the bibliometric analysis method, no human or animal subjects
59 were involved; therefore, ethical committee approval was not required.

60 The data used in this study were obtained from the Web of Science Core Collection
61 (WoSCC) database. The dataset was created by entering the following search terms into the
62 WoSCC database: ((scintigraphy OR SPECT OR PET OR radionuclide) AND (TMJ OR TMD
63 OR temporomandibular OR condyle OR "temporomandibular joint") AND (mandible OR
64 mandib* OR maxilla* OR jaw OR dentistry OR maxillofacial)). In order to ensure the
65 homogeneity of the dataset, conference proceedings, editorial letters, and studies unrelated to the
66 subject were excluded. The dataset was generated based on articles published between 1995 and
67 2025.

68 R (version 4.6.0), RStudio, and the Bibliometrix package (version 5.3.0) through
69 Biblioshiny were used for the bibliometric analysis. Within the scope of performance analysis,
70 Annual Scientific Production and Most Cited Documents Analysis were evaluated. In order to
71 investigate the conceptual structure of the field, Keyword Co-occurrence Analysis, Thematic
72 Map Analysis, and Thematic Evolution Analysis were performed.

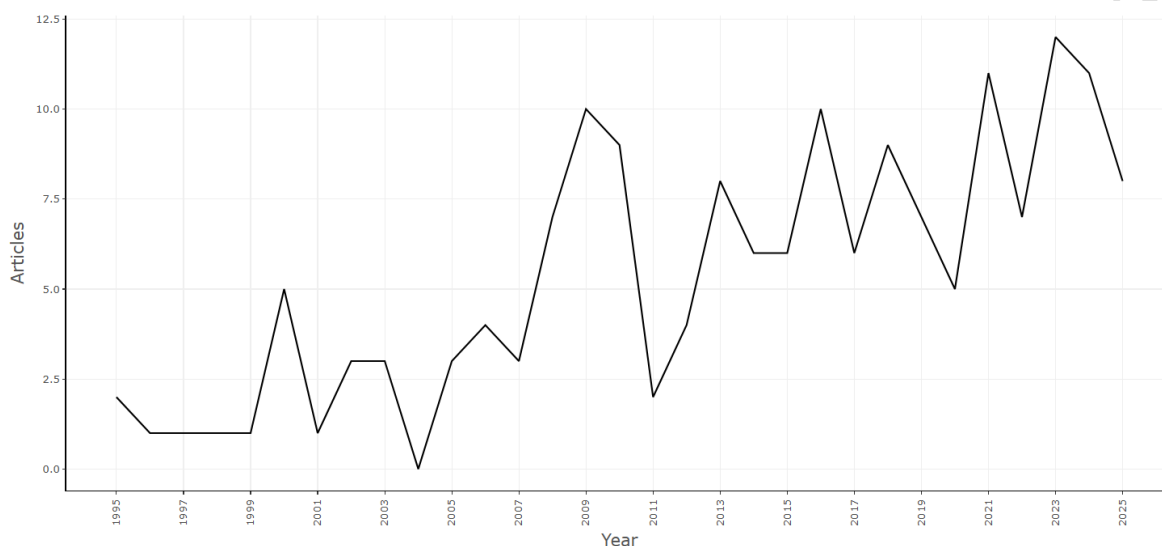
73 The conceptual structure of the field was examined using network-based clustering
74 approaches. In the Keyword Co-occurrence Analysis, only author keywords were included.
75 During the analysis, the colors within the generated network structure represented different
76 thematic groups, the node size indicated keyword frequency, and the edge thickness represented
77 the strength of co-occurrence. Within the scope of the Thematic Map Analysis, basic themes,
78 motor themes, niche themes, and emerging/declining themes were evaluated. In addition, the
79 development of existing themes over time was investigated through Thematic Evolution
80 Analysis.

81 **Results:** A total of 167 articles indexed in the WoSCC database were included in the study. Until
82 2004, the annual scientific production remained relatively lower compared to subsequent years,

83 whereas a general increasing trend accompanied by fluctuations was observed in the following
 84 years. The lowest annual scientific production was recorded in 2004, while the highest annual
 85 scientific production was reached in 2023 (Figure 1).

86

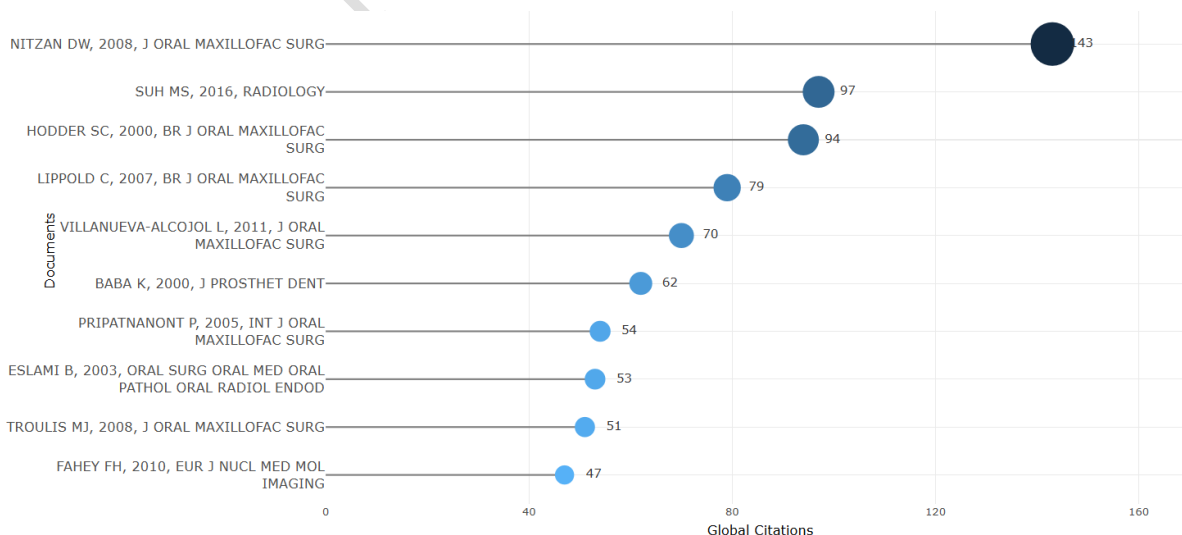
87



88

89 **Figure 1.** Annual Scientific Production Related to Radionuclide Imaging Methods in Temporomandibular Joint
 90 Research Between 1995 and 2025.

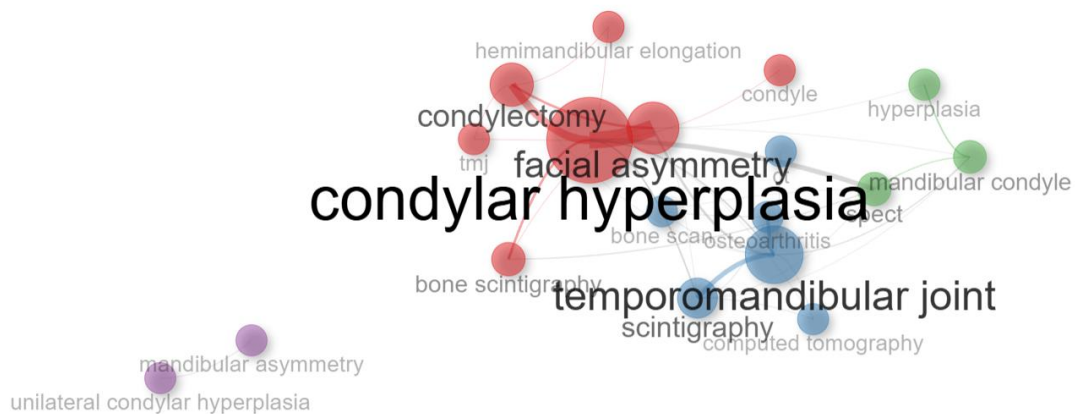
91 Evaluation of the Most Globally Cited Documents Analysis revealed that the study by
 92 Nitzan et al.(10)had the highest number of citations with 143 citations, followed by the study by
 93 Suh et al.(18)with 97 citations and the study by Hodder et al.(19)with 94 citations (Figure 2).



94

95 **Figure 2.** Most Globally Cited Documents Related to Radionuclide Imaging Methods in Temporomandibular Joint
96 Research.

97 Evaluation of the Authors' Keywords Co-occurrence Analysis demonstrated that the term
98 "condylar hyperplasia" was located at the center of the generated network and exhibited a high
99 degree of connection density. This term showed strong associations with the terms
100 "temporomandibular joint," "scintigraphy," "facial asymmetry," and "condylectomy" (Figure 3).

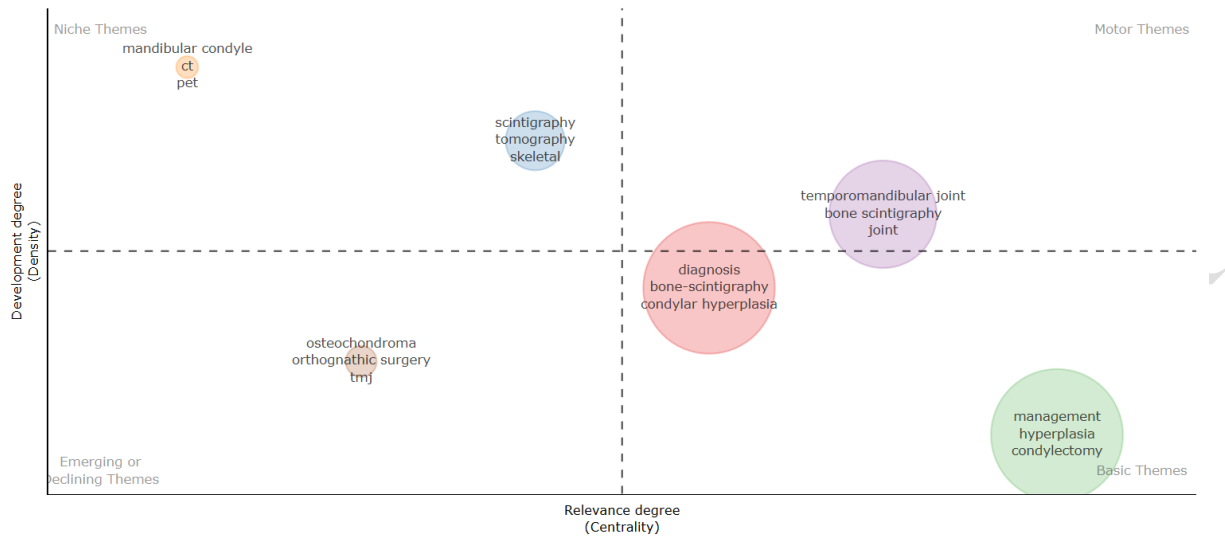

101
102 **Figure 3.** Authors' Keywords Co-occurrence Network Related to Radionuclide Imaging Methods in
103 Temporomandibular Joint Research.

104 Evaluation of the Thematic Map Analysis in the present study demonstrated that the
105 terms "temporomandibular joint," "bone scintigraphy," and "joint" were located in the motor
106 themes area, whereas the terms "management," "hyperplasia," "condylectomy," "diagnosis,"
107 "bone-scintigraphy," and "condylar hyperplasia" were positioned within the basic themes area.
108 In addition, the terms "mandibular condyle," "CT," "PET," "scintigraphy," "tomography," and
109 "skeletal" were identified in the niche themes area, while the terms "osteochondroma,"
110 "orthognathic surgery," and "TMJ" were located in the emerging/declining themes region

111 (Figure

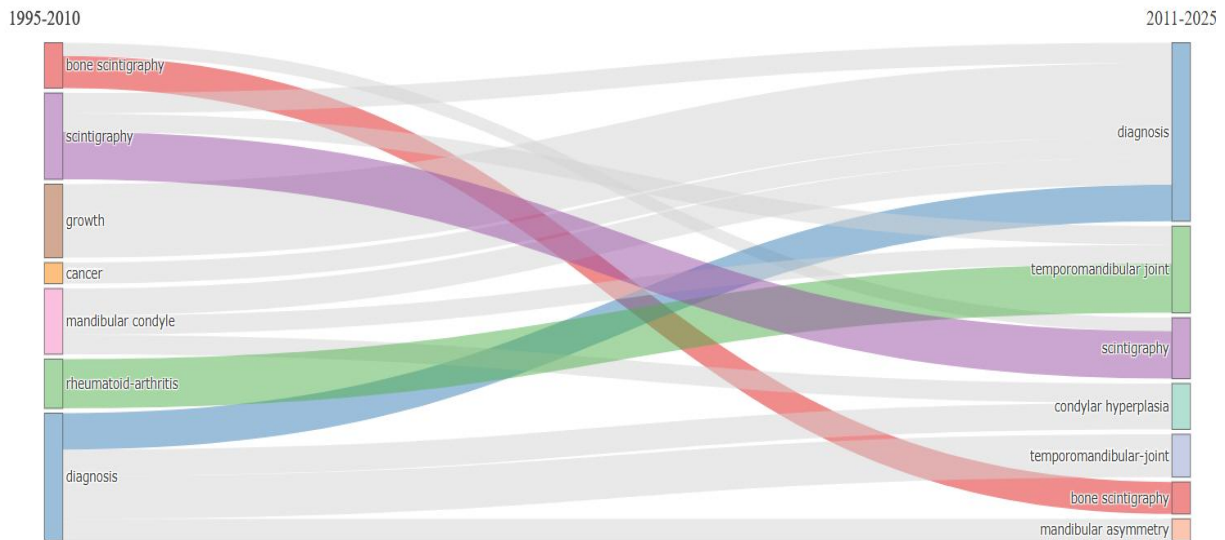
4).



112

113 **Figure 4.** Thematic Map Related to Radionuclide Imaging Methods in Temporomandibular Joint Research.

114 Evaluation of the Thematic Evolution Analysis demonstrated that, during the early
115 period, the themes “diagnosis,” “scintigraphy,” “bone scintigraphy,” “mandibular condyle,”
116 “growth,” “rheumatoid arthritis,” and “cancer” were prominent. In the later period, the terms
117 “diagnosis” and “scintigraphy” maintained their presence, while the themes “temporomandibular
118 joint,” “condylar hyperplasia,” “bone scintigraphy,” and “mandibular asymmetry” became more
119 prominent (Figure 5).



120

121 **Figure 5.** Thematic Evolution Related to Radionuclide Imaging Methods in Temporomandibular Joint Research.

122 **Discussion:** Nuclear medicine imaging methods are techniques that enable the diagnosis of
123 pathological conditions by utilizing the radioactive decay properties of radioisotopes. Nuclear

124 medicine represents a specialized field across all areas of healthcare and has great diagnostic
125 importance through modalities such as scintigraphy, Positron Emission Tomography, and Single
126 Photon Emission Computed Tomography. This importance also extends to dentistry. In these
127 methods, the distribution of administered radioactive isotopes is evaluated using specialized
128 scanners. Although there are studies regarding this field in dentistry, a lack of awareness still
129 exists (13, 14, 20, 21). In addition, since this is a developing field, there is limited information
130 regarding its scientific production, conceptual structure, and thematic evolution. Therefore, it is
131 necessary to evaluate the conceptual structure and current status of the field.

132 Evaluation of the Annual Scientific Production related to nuclear imaging methods in
133 dentistry demonstrated a general increasing trend over the years despite the presence of
134 fluctuations. This trend may be associated with the growing interest in functional imaging
135 methods for the evaluation of temporomandibular joint disorders. The ability of nuclear medicine
136 imaging modalities to assess metabolic activity in conditions such as condylar hyperplasia,
137 osteoarthritis, and inflammatory temporomandibular joint diseases may have contributed to the
138 expansion of their applications in dentistry. In addition, the fluctuations observed in annual
139 scientific production may be related to the fact that the field has developed around certain
140 specific clinical topics(14, 22, 23).

141 Evaluation of the Most Globally Cited Documents Analysis revealed that the most highly
142 cited studies were focused on temporomandibular joint imaging(10, 18, 19). This finding
143 suggests that the evaluation of the temporomandibular joint using nuclear medicine imaging
144 methods holds an important place in the field of dentistry.

145 Evaluation of the Authors' Keywords Co-occurrence Analysis regarding the present topic
146 demonstrated that the term "condylar hyperplasia" played a central role within the network
147 structure with a high degree of connection density. In particular, the strong associations of the
148 terms "scintigraphy," "facial asymmetry," and "condylectomy" with "condylar hyperplasia"
149 suggest that the field has been shaped around temporomandibular joint pathologies, facial
150 asymmetry, and surgical planning. In addition, the presence of the term "computed tomography"
151 within the network structure indicates the current position of hybrid imaging methods in the
152 field(22, 24).

153 Evaluation of the Thematic Map Analysis demonstrated that the terms
154 "temporomandibular joint," "bone scintigraphy," and "joint" were located within the motor
155 themes cluster. This finding indicates that scintigraphy-based imaging methods are among the
156 current and extensively investigated themes in the evaluation of joint disorders within the
157 literature(22). The themes "diagnosis," "bone-scintigraphy," "condylar hyperplasia,"
158 "management," and "condylectomy" were located within the basic themes cluster. This finding
159 indicates that these are research themes with a high degree of centrality and demonstrates that
160 radionuclide imaging methods are important not only for diagnostic purposes but also in relation
161 to surgical treatments(25, 26).The placement of the terms "CT," "PET," "scintigraphy,"

162 “tomography,” “mandibular condyle,” and “skeletal” within the niche themes cluster indicates
163 that hybrid and advanced radionuclide imaging methods are concentrated around specific
164 research areas in temporomandibular joint imaging(27).The positioning of the terms
165 “osteochondroma” and “orthognathic surgery” within the emerging/declining themes cluster
166 indicates that these areas have been investigated to a limited extent in the literature but represent
167 specific research topics that are important in terms of particular clinical applications(28, 29).

168 Evaluation of the Thematic Evolution Analysis demonstrated that, during the early
169 period, the terms “bone scintigraphy,” “scintigraphy,” “growth,” “mandibular condyle,”
170 “rheumatoid arthritis,” and “diagnosis” were prominent. This finding suggests that the research
171 focus was directed toward the evaluation of temporomandibular joint growth activity and
172 inflammatory joint diseases using scintigraphy. In later periods, the emphasis on the terms
173 “condylar hyperplasia,” “bone scintigraphy,” and “mandibular asymmetry” indicates that the
174 research field became concentrated on the assessment of temporomandibular joint metabolic
175 activity and the evaluation of facial asymmetry. The presence of the terms “diagnosis” and
176 “scintigraphy” in both periods demonstrates that the evaluation of the temporomandibular joint
177 through scintigraphy has remained a long-standing focus of research.

178 The limitations of this study include the creation of the dataset through searches
179 performed only in the WoSCC database using English-language terms. However, the fact that
180 English is the most widely used language in the literature and that the WoSCC database has high
181 indexing standards increases the reliability of the study.

182 **Conclusion:** In conclusion, the obtained data demonstrated an increase in annual scientific
183 production. Overall, the literature was found to be mainly concentrated on temporomandibular
184 joint hyperplasia and scintigraphy. Future studies are recommended to include search terms in
185 different languages and to incorporate different databases.

186 References

- 187 1. Merrick MV. Essentials of nuclear medicine: Springer Science & Business Media; 2012.
- 188 2. Lundberg TM, Gray PJ, Bartlett ML. Measuring and minimizing the radiation dose to nuclear medicine
189 technologists. *Journal of nuclear medicine technology*. 2002;30(1):25-30.
- 190 3. Erdoğan Ç, Akay G. Nuclear Imaging Applications in Dentistry. *ADO Klinik Bilimler Dergisi*.
191 2024;13(3):562-9.
- 192 4. Mallya S, Lam E. *White and Pharoah's Oral Radiology: Principles and Interpretation*: Mosby; 2018.
- 193 5. Jo JH, Bae S, Gil J, Oh D, Park S, Cheon GJ, et al. Limited implication of initial bone scintigraphy on
194 long-term condylar bone change in temporomandibular disorders—Comparison with cone beam computed
195 tomography at 1 year. *Journal of Oral Rehabilitation*. 2021;48(8):880-90.
- 196 6. Coutinho A, Fenyó-Pereira M, Dib LL, Lima ENP. The role of SPECT/CT with 99mTc-MDP image fusion
197 to diagnose temporomandibular dysfunction. *Oral Surgery, Oral Medicine, Oral Pathology, Oral Radiology, and*
198 *Endodontology*. 2006;101(2):224-30.
- 199 7. Wassef HR, Colletti PM. Nuclear medicine imaging in the dentomaxillofacial region. *Dental Clinics*.
200 2018;62(3):491-509.
- 201 8. Jeong H-J, Cho B-H, Jung Y-H. Comparison of planar scintigraphy and bone SPECT with clinical findings
202 and other imaging modalities in temporomandibular disorder patients. *Korean Journal of Oral and Maxillofacial*
203 *Radiology*. 2004:91-7.

204 9. Ahn B-C, Kim H-J, Lee S-W, Yoo J, Choi J-K, Lee J. New quantitative method for bone tracer uptake of
205 temporomandibular joint using Tc-99m MDP skull SPECT. *Annals of nuclear medicine*. 2009;23(7):651-6.

206 10. Nitzan DW, Katsnelson A, Bermanis I, Brin I, Casap N. The clinical characteristics of condylar
207 hyperplasia: experience with 61 patients. *Journal of Oral and Maxillofacial Surgery*. 2008;66(2):312-8.

208 11. Saridin C, Rajmakers P, Al Shamma S, Tuinzing D, Becking A. Comparison of different analytical
209 methods used for analyzing SPECT scans of patients with unilateral condylar hyperactivity. *International journal of*
210 *oral and maxillofacial surgery*. 2009;38(9):942-6.

211 12. Lee J, Lee S, Kim SJ, Choi J, Baek K. Clinical utility of fluoride-18 positron emission tomography/CT in
212 temporomandibular disorder with osteoarthritis: comparisons with 99mTc-MDP bone scan. *Dentomaxillofacial*
213 *Radiology*. 2013;42(2):29292350.

214 13. Buch SA, Babu SG, Castelino RL, Rao S, Madiyal A, Bhat S. Nuclear imaging in the field of dentistry: A
215 review. 2017.

216 14. Rajbaran Singh S, Gutta AA. A Review of the role of Nuclear Medicine Imaging in Diagnostic Dentistry.
217 *South African Dental Journal*. 2021;76(10):624-31.

218 15. Ellegaard O. The application of bibliometric analysis: disciplinary and user aspects. *Scientometrics*.
219 2018;116(1):181-202.

220 16. Donthu N, Kumar S, Mukherjee D, Pandey N, Lim WM. How to conduct a bibliometric analysis: An
221 overview and guidelines. *Journal of business research*. 2021;133:285-96.

222 17. Passas I. Bibliometric analysis: the main steps. *Encyclopedia*. 2024;4(2).

223 18. Suh MS, Lee WW, Kim Y-K, Yun P-Y, Kim SE. Maximum standardized uptake value of 99mTc
224 hydroxymethylene diphosphonate SPECT/CT for the evaluation of temporomandibular joint disorder. *Radiology*.
225 2016;280(3):890-6.

226 19. Hodder S, Rees J, Oliver T, Facey P, Sugar A. SPECT bone scintigraphy in the diagnosis and management
227 of mandibular condylar hyperplasia. *British Journal of Oral and Maxillofacial Surgery*. 2000;38(2):87-93.

228 20. Shreenivasamurthy P, Shastry SL. Nuclear medicine in orofacial diagnosis: A review. *Journal of Medicine,*
229 *Radiology, Pathology and Surgery*. 2016;2(4):12-6.

230 21. Stefanache A, Mihai C, Lungu II, Calin G, Mihalache C, Grigorii D, et al. EVOLUTION AND
231 APPLICATIONS OF RADIOPHARMACEUTICALS IN NUCLEAR DENTISTRY: A COMPREHENSIVE
232 OVERVIEW. *Romanian Journal of Oral Rehabilitation*. 2024;16(1).

233 22. Yang Z, Reed T, Longino BH. Bone scintigraphy SPECT/CT evaluation of mandibular condylar
234 hyperplasia. *Journal of nuclear medicine technology*. 2016;44(1):49-51.

235 23. Kim J-Y, Lee C, Park YL, Lee J-H, Ryu YH, Huh J-K. Diagnostic criteria for temporomandibular joint
236 osteoarthritis using standardized uptake value in single-photon emission computed tomography-computed
237 tomography. *Scientific Reports*. 2024;14(1):31569.

238 24. López DF, Ríos Borrás V, Muñoz JM, Cardenas-Perilla R, Almeida LE. SPECT/CT Correlation in the
239 diagnosis of unilateral condilar hyperplasia. *Diagnostics*. 2021;11(3):477.

240 25. Wen B, Shen Y, Wang C-Y. Clinical Value of 99Tcm-MDP SPECT Bone Scintigraphy in the Diagnosis of
241 Unilateral Condylar Hyperplasia. *The Scientific World Journal*. 2014;2014(1):256256.

242 26. Rodriguez I, Mut F. Quantitative bone SPECT analysis of mandibular condyles in an asymptomatic
243 population: An approach to normal reference values. *International Journal of Oral and Maxillofacial Surgery*.
244 2021;50(6):733-9.

245 27. Israel O, Pellet O, Biassoni L, De Palma D, Estrada-Lobato E, Gnanasegaran G, et al. Two decades of
246 SPECT/CT—the coming of age of a technology: an updated review of literature evidence. *European journal of*
247 *nuclear medicine and molecular imaging*. 2019;46(10):1990-2012.

248 28. Follacchio GA, Ricci M, Ramieri V, Vellone V, Frantellizzi V, Liberatore M, et al. Unilateral condylar
249 hyperplasia recurrence after orthognathic surgery: a case report. *RADIOLOGY AND DIAGNOSTIC IMAGING*.
250 2017;1(2):1-4.

251 29. Yamamoto FP, Silva BSdF, Modes RW, Fonseca FP, Pontes FSC, de Sousa SCO. Computed tomography
252 and scintigraphy exams for diagnosis and treatment planning of the condylar osteochondroma: A case report.
253 *Revista Odonto Ciência*. 2010;25:422-6.

254