

1 When All Tests Are Normal: Steroid Responsiveness as a Key Diagnostic Argument for 2 Multiple Sclerosis in Pediatric Optic Neuritis

3 4 **Abstract**

5 6 **Background:**

7 Pediatric optic neuritis (ON) represents a diagnostic challenge, particularly when extensive
8 investigations fail to identify a clear etiology. While imaging and laboratory findings are
9 central to diagnosis, clinical reasoning and therapeutic response may play a decisive role.

10 11 **Case presentation:**

12 We report a 14-year-old girl presenting with acute unilateral visual loss of the right eye
13 associated with headache and pain on eye movement. Clinical examination revealed anterior
14 optic neuropathy with stage II optic disc edema.

15 A comprehensive ophthalmologic, neurological, infectious, and immunological workup was
16 performed. Brain and orbital MRI showed inflammatory involvement of the right optic nerve
17 without evidence of disseminated lesions. Cerebrospinal fluid analysis and extensive
18 autoimmune and infectious testing were unremarkable.

19 20 **Management and outcome:**

21 High-dose intravenous methylprednisolone resulted in rapid and marked visual recovery,
22 with resolution of optic disc edema.

23 24 **Conclusion:**

25 This case highlights that, in the absence of definitive paraclinical evidence, the diagnosis of
26 demyelinating optic neuritis suggestive of multiple sclerosis may rely on clinical presentation
27 and therapeutic response. Steroid responsiveness should be considered a major diagnostic
28 argument in such cases.

29 30 **Keywords:**

31 Optic neuritis; Pediatric; Multiple sclerosis; Steroid response; Diagnostic challenge

32 33 **Introduction**

34 Optic neuritis (ON) is an inflammatory disorder of the optic nerve frequently associated with
35 demyelinating diseases, particularly multiple sclerosis (MS). In adults, diagnosis is often
36 supported by magnetic resonance imaging (MRI) and cerebrospinal fluid (CSF) abnormalities
37 demonstrating dissemination in space and time.

38 However, pediatric ON differs in presentation and often lacks definitive paraclinical markers
39 at initial evaluation. In such cases, the diagnostic process becomes more complex, requiring
40 a careful integration of clinical, radiological, biological, and therapeutic data.

41 Importantly, a rapid and significant response to corticosteroid therapy is recognized as a
42 characteristic feature of inflammatory demyelinating optic neuritis and may contribute to
43 the diagnostic orientation toward MS.

44 We report a case of pediatric optic neuritis in which all investigations were inconclusive, and
45 the diagnosis relied primarily on clinical findings and a striking response to corticosteroids.

46
47

48 **Case Report**

49 A 14-year-old girl presented with acute visual loss in the right eye evolving over five days.
50 The condition was associated with headache and pain on ocular movement.

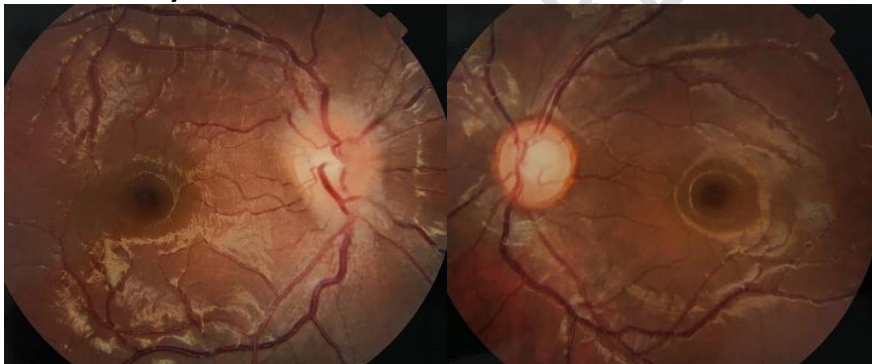51 **Medical history**

- 52 • Iron deficiency anemia for 18 months (poor compliance with treatment)
- 53 • Menstrual cycle disorders (hypermenorrhea and irregular cycles)
- 54 • Refractive amblyopia in the left eye
- 55 • Recent upper respiratory tract infection 10 days prior

56

57 **Clinical Examination**

- 58 • **Visual acuity:**
 - 59 ○ Right eye: counting fingers at 2 meters (non-improvable)
 - 60 ○ Left eye: 5/10
- 61 • **Pupillary reflex:**
 - 62 ○ Relative afferent pupillary defect in the right eye
- 63 • **Intraocular pressure:** normal bilaterally
- 64 • **Anterior segment:** normal
- 65 • **Fundus examination (right eye):**
 - 66 ○ Stage II optic disc edema
 - 67 ○ Blurred margins
 - 68 ○ Papillary hyperemia
 - 69 ○ Venous dilation and tortuosity
 - 70 ○ Absence of hemorrhages or exudates
- 71 • **Left eye:** normal



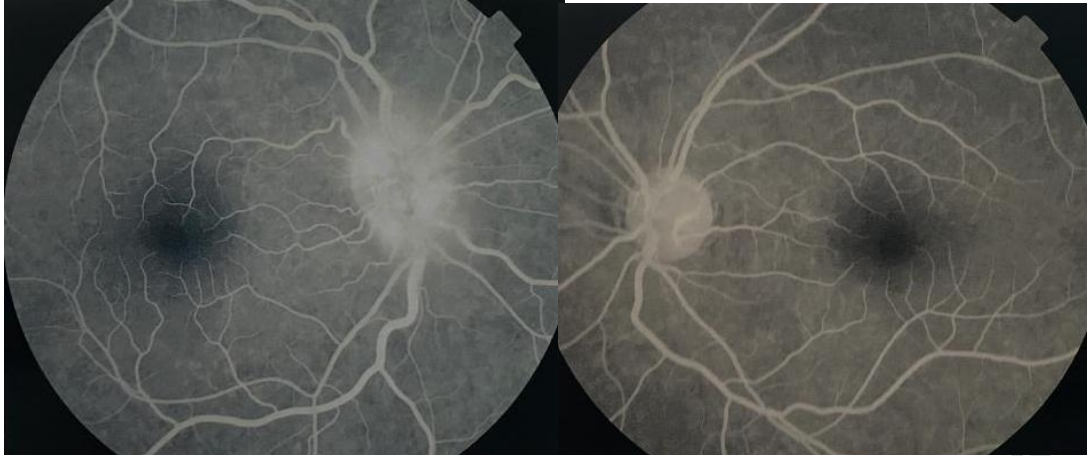72

73 **Ophthalmologic Investigations**

74 **Fluorescein Angiography**

- 75 • Papillary leakage
- 76 • Peripapillary diffusion
- 77 • Venous dilation
- 78 → confirming inflammatory optic neuropathy

79

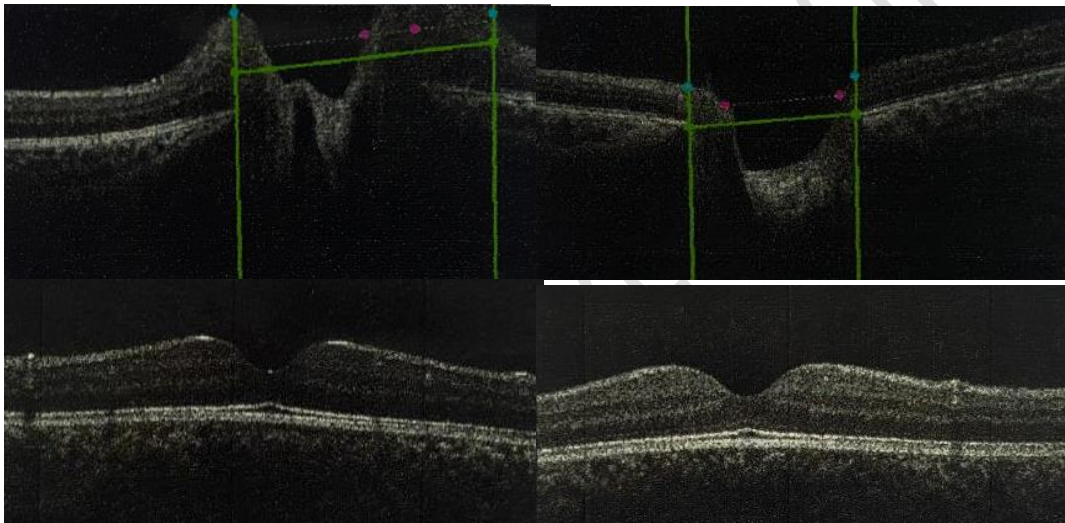


80

81 **Optical Coherence Tomography (OCT)**

- 82 • Increased optic disc thickness
- 83 • Reduction of physiological cupping
- 84 • Peripapillary RNFL thickening
- 85 • Macular OCT: normal

86




87

88

89

90 **Visual Field**

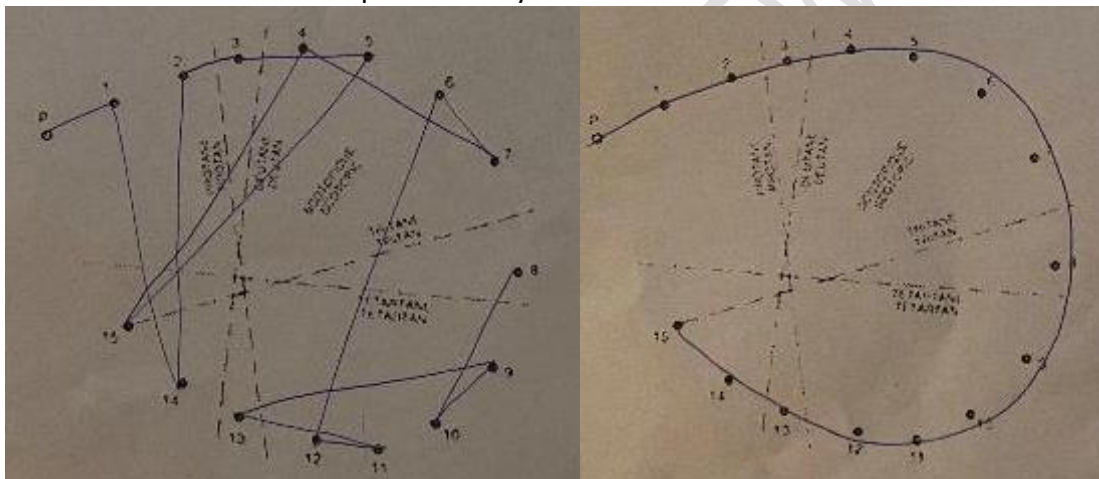
- 91 • Right eye: non-interpretable due to low visual acuity
- 92 • Left eye: learning test, arciform superior defect (to be confirmed)



93
94
95
96
97

Color Vision (Lanthony desaturated test)

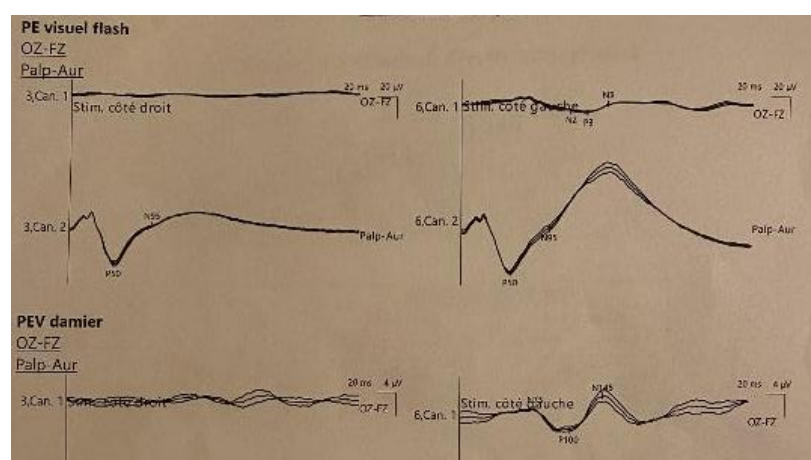
- Blue-yellow (tritan) deficit
 - Red-green (deutan) deficit
- consistent with optic nerve dysfunction



98
99
100
101
102
103
104
105

Visual Evoked Potentials (VEP)

- Right eye: abolition of P100 response
 - Left eye: delayed latency and reduced amplitude
- suggesting:
- Severe pre-chiasmatic involvement (right eye)
 - Subclinical involvement (left eye)
 - Possible demyelinating process

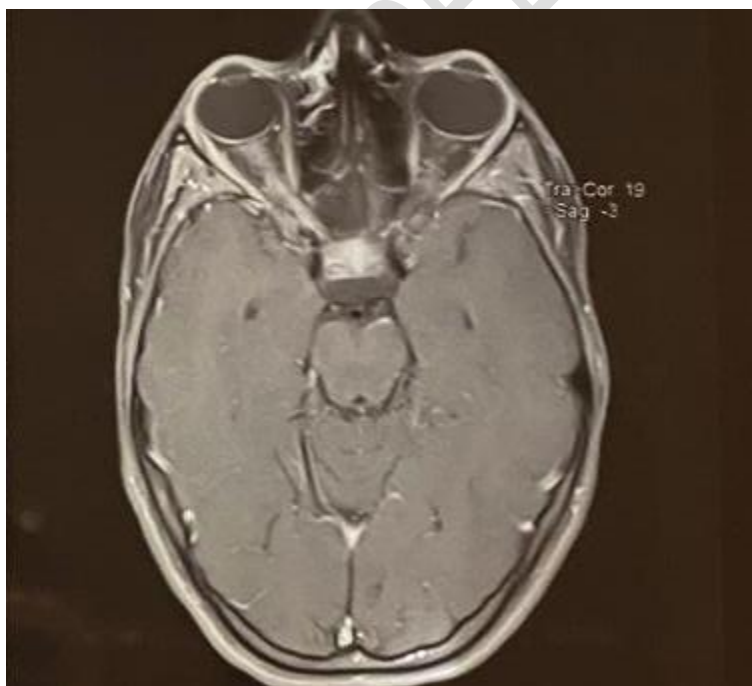


106
107
108
109
110
111
112
113

Neuro-imaging

MRI (brain and orbits)

- T2 and FLAIR hyperintensity of the right optic nerve
- Gadolinium enhancement
- Involvement of intraorbital, retrobulbar, intracanalalar, and prechiasmatic segments
- No demyelinating lesions elsewhere
- No compressive lesion



114

115 **Laboratory and Systemic Workup**

116 **Cerebrospinal Fluid**

- 117 • Normal cytology
- 118 • Normal protein and glucose
- 119 • Negative culture

120

121 **Biological Workup**

- 122 • Mild anemia (Hb 10.7 g/dL)
- 123 • Elevated ESR (52 mm/h)
- 124 • Normal CRP
- 125 • Low ferritin

126

127 **Infectious Workup**

- 128 • HIV, HSV, CMV, EBV: negative or immunized
- 129 • Syphilis, Lyme, toxoplasmosis: negative
- 130 • Tuberculosis (Quantiferon): negative

131 **Autoimmune Workup**

- 132 • ANA, anti-dsDNA, ANCA: negative
- 133 • Anti-MOG: negative
- 134 • Anti-AQP4: negative

135

136

137

138 **Differential Diagnosis**

- 139 • Demyelinating optic neuritis (MS, NMOSD)
- 140 • Infectious optic neuropathy
- 141 • Autoimmune systemic disease
- 142 • Compressive optic neuropathy
- 143 • Hereditary optic neuropathy

144 All alternative diagnoses were excluded.

145

146 **Management**

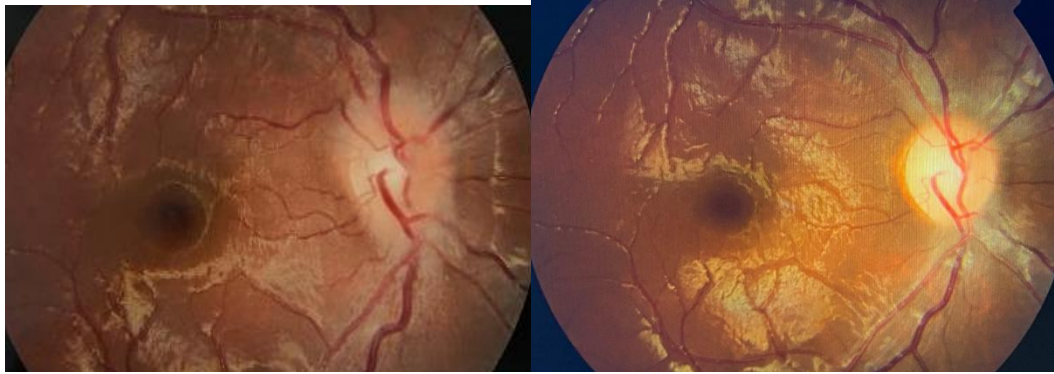
- 147 • Oral antibiotics for associated sinusitis
- 148 • Intravenous methylprednisolone (1 g/day for 3 days)
- 149 • Oral corticosteroid relay

150

151 **Outcome**

152 **Clinical evolution**


- 153 • Visual acuity improved from CF → 9/10
- 154 • Pupillary reflex normalized
- 155 • Resolution of optic disc edema



156
157
158

Visual field

- Improvement with residual central scotoma



159
160
161
162
163

Discussion

Pediatric optic neuritis is often diagnostically challenging due to the absence of typical radiological and biological markers at onset.

In this case:

- MRI did not demonstrate dissemination in space
- CSF was normal
- Autoimmune and infectious workups were negative

However, several clinical arguments strongly supported a demyelinating etiology:

- Acute unilateral visual loss
- Pain on eye movement
- Optic disc edema
- Relative afferent pupillary defect
- Bilateral electrophysiological involvement

Most importantly, the **rapid and marked response to corticosteroid therapy** represents a **well-recognized characteristic of inflammatory demyelinating optic neuritis and is considered an important diagnostic argument in favor of multiple sclerosis.**

177
178
179

180 This case highlights a crucial clinical principle:
181 **Diagnosis should not rely solely on paraclinical findings but must integrate clinical**
182 **reasoning and therapeutic response.**

183
184

185 **Conclusion**

186 This case illustrates the limitations of paraclinical investigations in pediatric optic neuritis.
187 Even in the absence of definitive diagnostic findings, a demyelinating etiology suggestive of
188 multiple sclerosis should be considered when clinical features are typical and when there is a
189 strong response to corticosteroid therapy.

190 Close follow-up is essential to confirm the diagnosis over time.

191

192 **References**

- 193 1. Beck RW, Cleary PA, Anderson MM Jr, et al. A randomized controlled trial of
194 corticosteroids in optic neuritis. *N Engl J Med.* 1992;326(9):581–588.
- 195 2. Optic Neuritis Study Group. The clinical profile of optic neuritis. *Arch Ophthalmol.*
196 1991;109(12):1673–1678.
- 197 3. Waldman AT, Liu GT. Pediatric optic neuritis. *Neurology.* 2010;74(1):S27–S32.
- 198 4. Petzold A, Plant GT. Diagnosis and classification of optic neuritis. *Lancet Neurol.*
199 2014;13(1):83–94.
- 200 5. Krupp LB, Tardieu M, Amato MP, et al. Pediatric multiple sclerosis. *Neurology.*
201 2013;80(13):121–127.
- 202

UNDER PEER REVIEW