

A diagnostic puzzle over time, post-traumatic ankle pain.

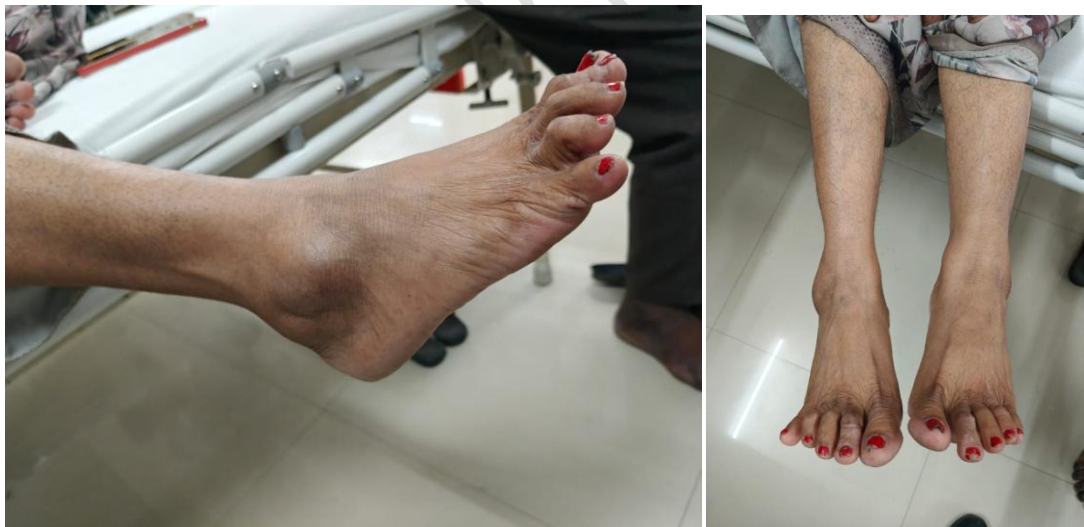Introduction

In this modern era where everyone is always on their toes, Ankle pain is one of the commonest complaints given by all age groups. This affects young to the elderly. It is seen in athletes as well as those having a sedentary life style

It may present as just discomfort in the ankle. This may occur due to many reasons commonly being injuries, arthritis, over use causing wear and tear. Depending on the cause there may be pain, stiffness, edema or swelling anywhere around the ankle leading to difficulty in putting weight over the ankle. Usually rest, ice or routine analgesics give good relief, but still any pain which persists for more than 6 weeks becomes chronic leading to chronic ankle pain.

Case Summary :

Case 1 - 55 years female came with complaints of chronic right ankle pain since past 6 months. She was involved in road traffic accident (between 2 two wheelers) 12 years ago and sustained a fall. There was minimal pain in both her lower limbs at the time of accident. Since past 6 months she has pain and discomfort in her right ankle along with swelling on the lateral aspect. The range of movement was full but painful. Distal neurovascular examination was normal.



Case 2- 21 year old male patient had H/O fall from stairs 8 years ago. He has chronic ankle pain since then which has aggravated since the past one year. There was tenderness over the left ankle and no e/o of any swelling or restricted range of movement (ROM). He complained of sensation of ankle giving way frequently.

23 **Case 3** – 51 year old male with H/O tyre of 2 wheeler going over his right ankle 3 years ago and
24 leading to chronic ankle pain since 6 months. He had painful and restricted ROM

25 **Case 4** - 12 year old male child with H/O fall in school play ground 2 years ago . He presented
26 with severe pain in right ankle since 2 months leading to difficulty in walking .

27 **Provisional Diagnosis :**

28 Chronic Right Ankle Pain secondary to Road Traffic Accident (RTA) with probable:

29 * Post-traumatic osteoarthritis of the right ankle

30 * Chronic lateral ankle instability (given long-standing pain and potential ligamentous injury
31 from RTA)

32 * Possible chronic ligamentous injury (e.g., ATFL, CFL)

33 * Possible impingement syndrome (anterior or posterior)

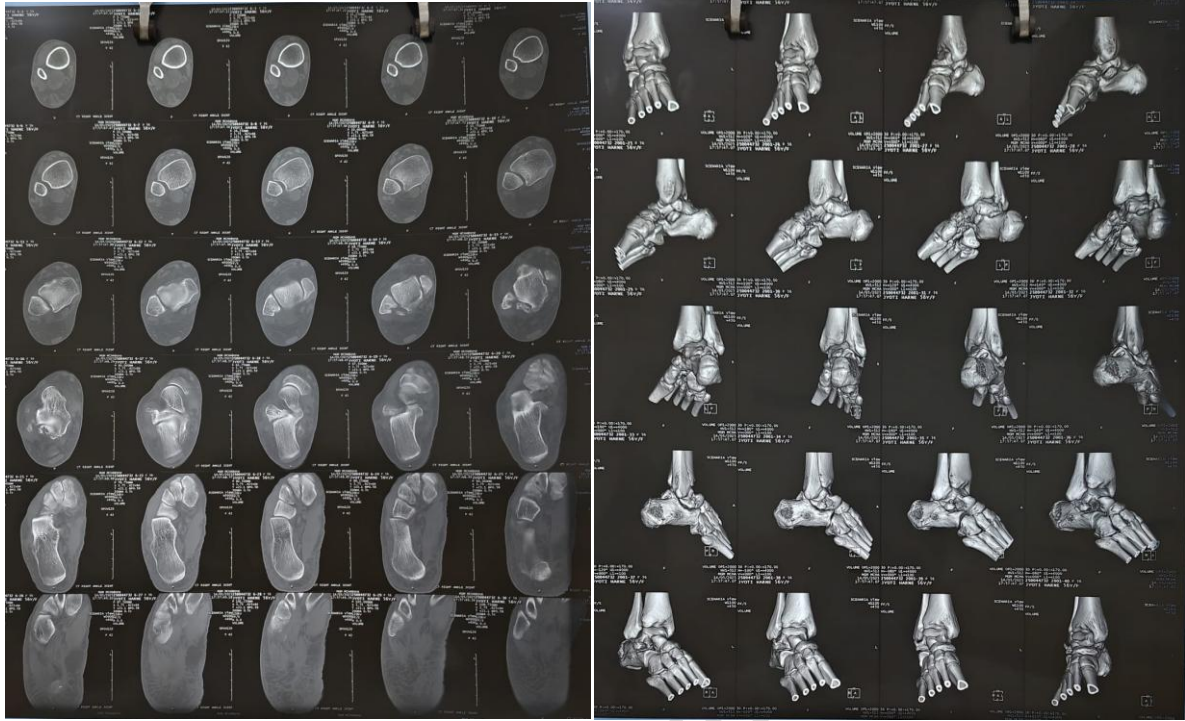
34 **Investigations:**

35 Based on the clinical H/O and examination , Radiological investigations were planned to assess
36 the bony changes and evaluate soft tissue structure . X-ray of the ankle revealed -----

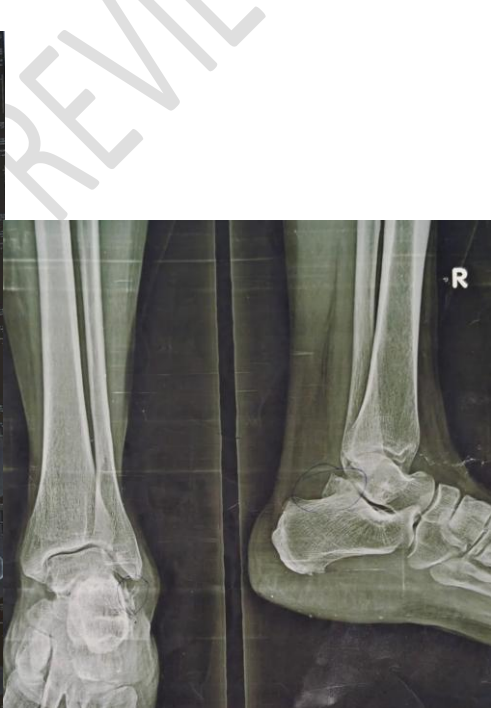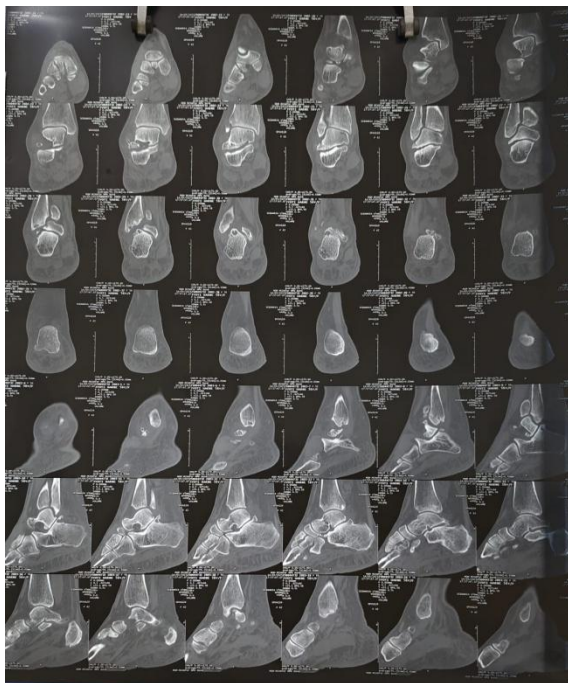37 MRI of the ankle showed periarticular osteophytes which was suggestive of arthritis

38 Findings were conclusive with post traumatic degenerative changes in the ankle joint along with
39 formation of osteophytes

40



41



Pre operative xray- right anke joint

42

43

44

45

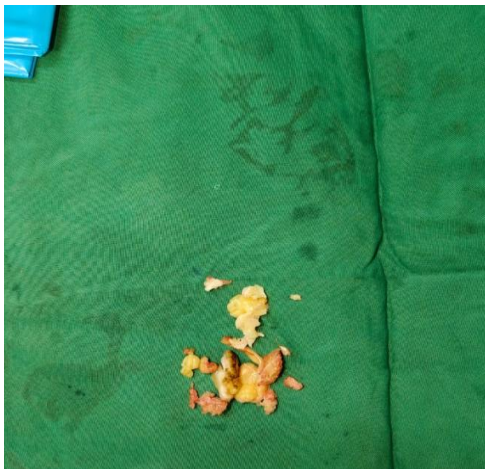46

47 **Management :**

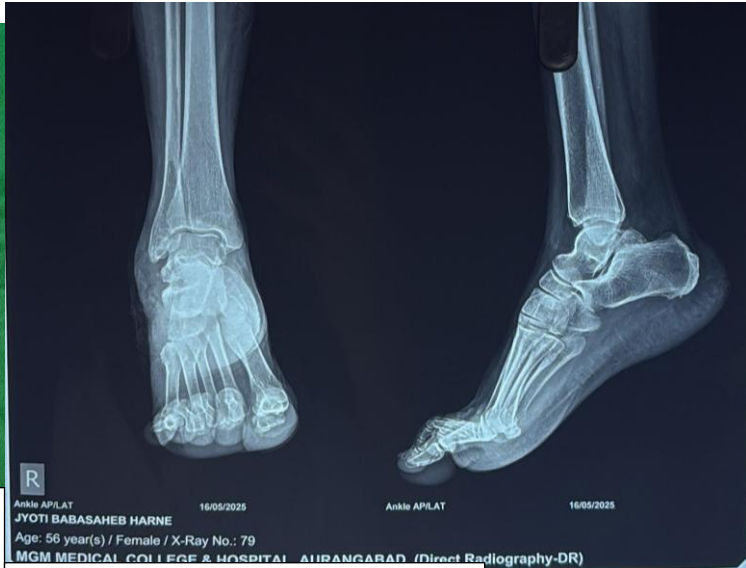48

49 Before investigations all the patients had taken treatment in the form of NSAIDS and Cold
50 fomentation

51 Based on the radiological findings and long standing systems , surgical management for all
52 patients was planned , which consisted of ankle joint debridement and osteophytes excision.



53 **Post operative image showing removed
54 osteophytes**



55 **Discussion :**

56 Post traumatic degenerative changes are a common cause of chronic ankle pain .The reason is
57 incomplete healing after an injury or a sprained ankle . Chronic ankle pain is widely prevalent
58 and causes include tendonitis , Achilles tendon ruptures , bursitis , arthritis , tarsal tunnel
59 syndrome , gout , rheumatoid arthritis and anterior impingement syndrome. It usually presents as
60 a persistent dull ache or a sharp stabbing pain leading to difficulty in walking specially on an
61 uneven surface.

62 Post traumatic development of osteophytes are commonly seen but in our study , Patients gave
63 symptoms after a very long duration . Some of them considered the primary injury as negligible
64 and of no importance.

65 Osteophytes are bone spurs which develops as smooth bony outgrowths along the joint edges
66 causing stiffness in movements along with variable degree of pain and restricted ROM. They
67 are usually form due to osteophytosis when the body creates new bone tissue to replace the
68 damage tissue . These osteophytes usually do not cause any problems , but when they irritate the
69 nerves and soft tissue , then symptoms appear . Bony spurs or osteophytes are a biproductof the
70 repair processes which may cause complicationslike radiculopathy consisting of paresthesia and
71 muscle weakness .

72

73

74 **Conclusion :**

75

76 This study highlights the significance of remote trauma in the development of osteophytes
77 leading to
78 persistent chronic ankle pain . The findings of this research study demonstrate the potential
79 impact of early detection and early intervention in the management of chronic ankle pain . In
80 conclusion timely imaging and prompt surgical osteophyte excision can help relief symptoms
81 and give healthy life to the patient.

82

83

84

85

86

87 **References :**

- 88 1. Valderrabano V, Horisberger M, Russell I, Dougall H, Hintermann B. Etiology of ankle
89 osteoarthritis. Clin OrthopRelat Res. 2009 Jul;467(7):1800-6. doi: 10.1007/s11999-008-
90 0543-6. Epub 2008 Oct 2. PMID: 18830791; PMCID: PMC2690733.
- 91 2. Herrera-Pérez M, González-Martín D, Vallejo-Márquez M, Godoy-Santos AL,
92 Valderrabano V, Tejero S. Ankle Osteoarthritis Aetiology. J Clin Med. 2021 Sep
93 29;10(19):4489. doi: 10.3390/jcm10194489. PMID: 34640504; PMCID: PMC8509242.
- 94 3. Saltzman CL, Salamon ML, Blanchard GM, Huff T, Hayes A, Buckwalter JA, Amendola
95 A. Epidemiology of ankle arthritis: report of a consecutive series of 639 patients from a
96 tertiary orthopaedic center. Iowa Orthop J. 2005;25:44-6. PMID: 16089071; PMCID:
97 PMC1888779.